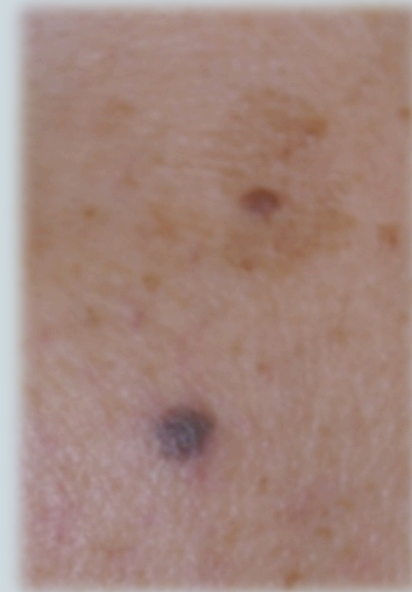
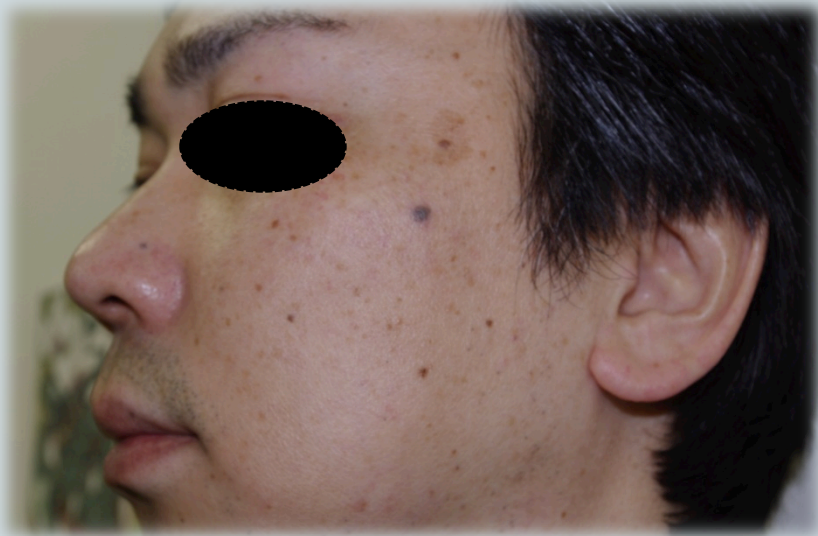
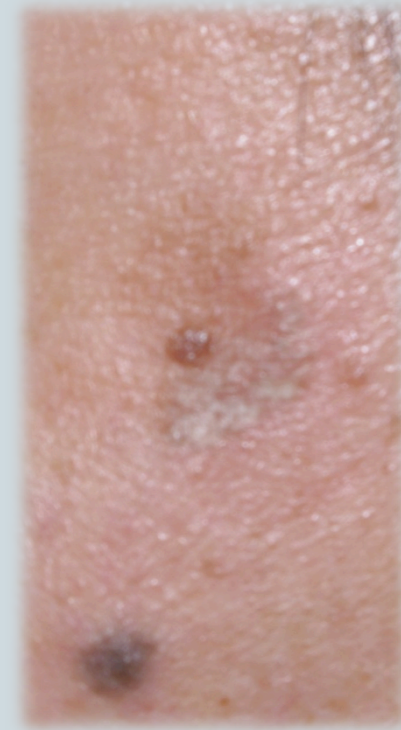
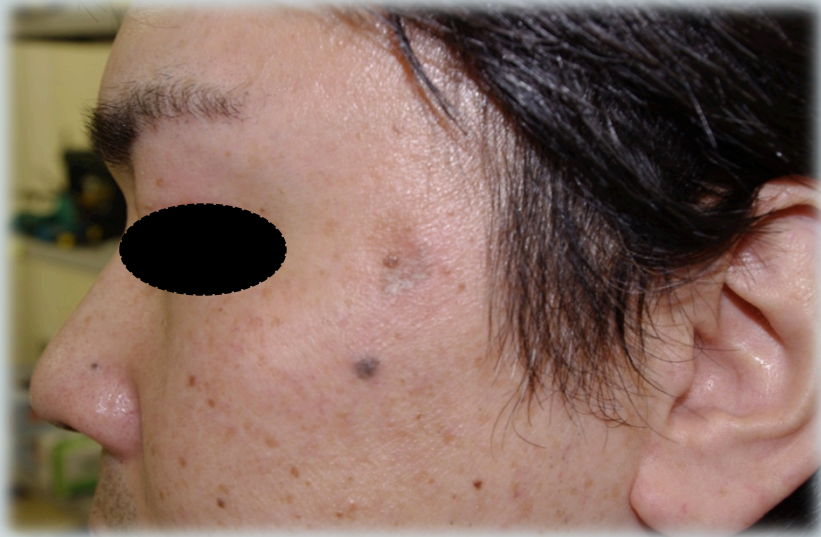

532nm波長による老人性色素斑治療

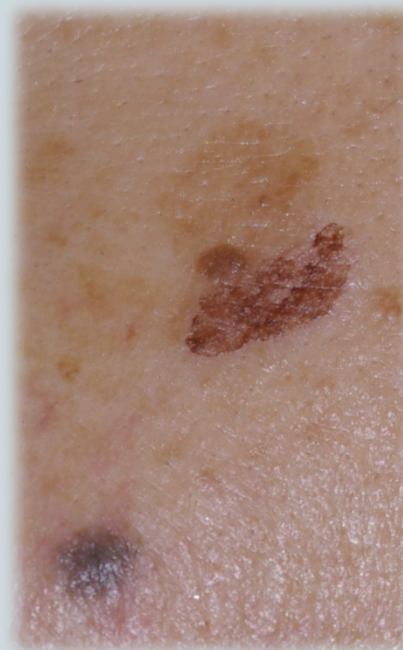
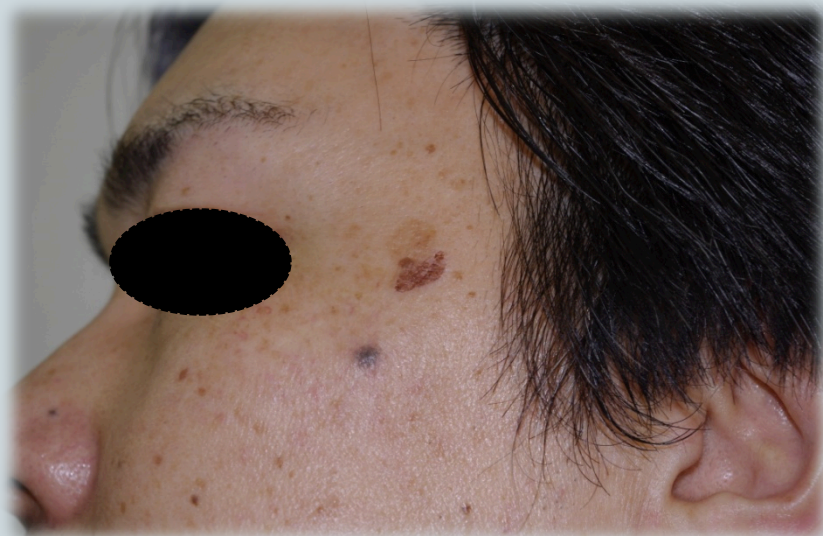
照射前



照射直後 (若干の白変を確認)



照射 3 日後 (痂皮化)



照射9日後 (痂皮脱落)

